

ASIA-PACIFIC CONFERENCE in FUKUOKA 2014

International Symposium on Oral Education and Research in Kitakyushu



HELSINGIN YLIOPISTO
HELSINGFORS UNIVERSITET
UNIVERSITY OF HELSINKI



Date : 25 January 2014 (Sat)

Venue: Kyushu Dental University, Kitakyushu Japan

Asia-Pacific Conference in Fukuoka 2014

International Symposium on Oral Education and Research in Kitakyushu

Kyushu Dental University, Kitakyushu, Japan
Jan 25th “2014

Organizing Committee:

Tatsuji Nishihara, President
Shin-ichi Masumi
Ryuji Hosokawa
Chiaki Kitamura
Yasuaki Kakinoki
Keisuke Nakashima
Shigeori Takenaka
Eijiro Jimi

Organized by Kyushu Dental University

Welcome message



Tatsuji Nishihara, D.D.S., Ph.D.
President
Kyushu Dental University

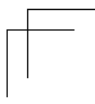
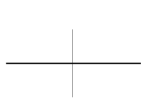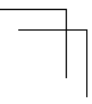
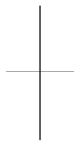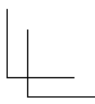
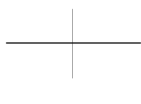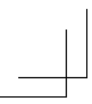It is our great honor and pleasure to invite you to the Asia-Pacific Conference in Fukuoka 2014, an International Symposium on Oral Education and Research in Kitakyushu, Japan, to be held on January 25th, 2014. I urge you to participate in this exciting project that successfully started last year to obtain valuable information concerning Oral Education and Research in various countries

We are delighted to announce two special lectures to be given at the conference. A speaker invited from Srinakharinwirot University, which has developed a new system for dental education, will introduce the present state of dental educational activity in Thailand. Another speaker, who has been invited from the University of Helsinki, will introduce examples of advances in oral health in Finland, providing us with an opportunity for comparison with the situation in Asian countries. We are expecting to have lively discussions, which may also include topics such as the social health care systems of each country.

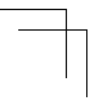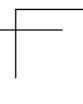
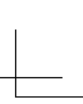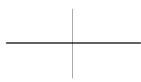Moreover, we are planning to have a session for presentations and invigorating discussions about the distinguished achievements in education and scientific research through between dentistry, medicine and biotechnology in the Kitakyushu area. It is our wish to offer innovative ideas for everyone and help build true partnerships among our various countries.

Table of Contents

Welcome	2
Program	5
Plenary Lectures	9
Poster Presentations	13



Program



13:00 Registration

13:20 Welcome Address and Opening Remarks
Prof. Tatsuji Nishihara (President of Kyushu Dental University)

13:30 - 16:00 Symposium
“International symposium on Clinical Training for Dentistry and Public Health Approaches to Aging Society”
Chairs: Keisuke Nakashima, Naoki Kakudate

Assoc. Prof. Narongsak Laosrisin (Srinakharinwirot University)
Dental Education System in Thailand

Prof. Heikki Murtomaa (University of Helsinki, Finland)
Dental Public Health: 1 +1 = 3

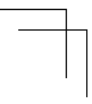
Assoc. Prof. Naoki Kakudate (Kyushu Dental University)
The current status and future direction of dental education in Japan

Coffee Break

16:15 - 17:10
Poster Sessions

17:15 Closing Remarks
Prof. Shin-ichi Masumi (Vice-President of Kyushu Dental University)

18:30 Banquet



Plenary Lectures



Dental Education System in Thailand

Narongsak Laosrisin

Faculty of Dentistry, Srinakharinwirot University

Thailand is one of ASEAN member's country with a size of 514,000 square kilometres and its population of 64.87 million. Dental education in Thailand has been first established since 1940 by Chulalongkorn university. Dentistry has been then developed in a short period of time, to ensure appropriate production of dentists and dental personals to serve oral health for its population. Still, the dental manpower was found to be in short supply, the production of dentists then has been increased dramatically and continually in the past 20 years. Recently, there are total of ten public and two private dental schools in Thailand, which two public and one private dental schools have been recently established last year. A six-year under graduate curriculum of dental education leads to the DDS degree and 1-3 years course of further study contribute the higher dental education in grade diploma/certificate, master and doctoral degree.

A major goal of this presentation is to make the participants understand the information about Thailand regarding its dental history, dental school system including curriculum, specialties and dental licensure.



Dental Public Health: 1 +1 = 3

Heikki Murtomaa

Department of Oral Public Health, Institute of Dentistry,
University of Helsinki, Finland

Oral diseases represent a major public health problem with considerable impact on individuals as well as societies and remain among the most expensive to treat. In addition there is a continuous imbalance in the distribution of oral health care services available; those least in need frequently receive most and those most in need receive the least of care and health education. The major oral diseases are today more clearly than ever understood as behaviour dependent diseases. Although the high risk of oral disease relates to several socio-cultural determinants the common risk factors for chronic diseases, including oral diseases, have been recognized. Control of oral diseases depends as well on oral health care system and its ability to sufficiently offer high quality, prevention oriented services to those in need as on the success of health promotion at large.

In spite of continuing process in convergence of dental education by the Association for Dental Education in Europe oral health delivery within EU countries coupled with the present health reforms represent a major challenge for public health education for dentists. In dental education there is a need to demonstrate the effect of socio-economic policies on the oral health of both individuals and communities to all students. The present courses reflect a variety of national attributes and socio-cultural factors and last but not the least the national oral disease panorama. Dental Public Health as a discipline should be recognized as a core subject in dental curricula helping dentists to understand their role and duties in society. This approach includes issues of health policy and administration, service delivery, health economics, epidemiology, statistics, informatics, ethics, behavioural sciences, communications, practice management and treatment of special need groups with emphasis on health promotion in communities. The need for this in the modern dental education is obvious.



The current status and future direction of dental education in Japan

Naoki Kakudate

Educational Cooperation Center, Kyushu Dental University

In 2011, the Science Council of Japan pointed out the major problems in current Japanese dental education as “securement of student enrollment”, “improvement of curriculum for dental education”, “development of a successor in charge of future dental education”, and “dentist education through life-long learning”. Due to the diversification of social needs and changes in dental disease structure, the qualities and skills required of dentists are diversified. Under the aegis of the Ministry of Education, Culture, Sports, Science and Technology, the model core curriculum determined the “qualities of a general dentist” consisting of “responsibility as a dentist”, “patient-centered point of view”, “communication skill”, “team dental care”, “community oral health-care”, “research mind”, and “self-improvement”. In the United States, “eight core principles of American Dental Education Association (ADEA)” consist of “critical thinking”, “lifelong and self-directed learning”, “humanistic environment”, “scientific discovery and the integration of knowledge”, “evidence-based oral health care”, “assessment”, “faculty development”, and “health care team”. Last year, the Commission on Dental Accreditation (CODA) defined the new accreditation standards for dental education programs as “2-21. Graduates must be competent to access, critically appraise, apply, and communicate scientific and lay literature as it relates to providing evidence-based patient care.” Therefore, all US dental schools promote education on Evidence-Based Dentistry (EBD), based on clinical epidemiology. Since EBD education is considered effective for enhancing the ability to think critically and develop life-long learning skills, its inclusion in Japanese dental education of the future is also considered important. Performing EBD and evidence-based education will lead to improvements in the quality of dental practice and dental education. On this basis, I propose the “hybrid-type dentist,” who has two additional competencies: “clinical skills with evidence-based dentistry” and “a research mind with clinical epidemiology”. Hybrid-type dentists who can both utilize and construct evidence will contribute to the future of the dental profession and enable the creation of a new era.

Poster Presentations

P-1

Study of a Novel Endoscopy for Dental Therapy

Shinji Yoshii¹, Tatsuji Nishihara², Chiaki Kitamura¹

¹Division of Endodontics, and Restorative Dentistry,

²Division of Infections and Molecular Biology, Kyushu Dental University

In dental therapy, observing the microstructure of the oral cavity is an important factor for successful treatment, and now diagnostic accuracy in endodontics has been improved by using microscopy or cone beam CT(CBCT). However, detection of cracks and collaterals of root canals remains difficult, because the microscope can only perform real-time observations from the outside of the oral cavity with many blind areas, and the CBCT cannot carry out real-time observation. In addition, the voxel size of CBCT is at most 80 micrometer.

In this study, we aimed to develop a novel and low cost diagnostic device with high resolution to detect fine structures both the inside and the outside of a tooth, as well as the periapical tissue and periodontal pockets. This device is capable of carrying out real time observation inside the narrow root canals of oral cavity with high precision without blind areas using a single graded-index image fiber (600 micrometer of diameter, 15000 pixels, and resolution is about 6 micrometer). The system uses the graded-index image fiber to irradiate the sample and to guide the sample image into the CMOS image sensor of the microscope simultaneously, in stead of conventional endoscope diagnostic system, which is both fibers for illumination and observation have been required separately. Proposed system is easy to make more compact owing to the coaxial configuration. The resolving power of the system is up to 10 micrometer. This precision is sufficient to detect cracks and collaterals of the root canals.

P-2

Anti-inflammatory effect of IL-1 receptor antagonist gene transfection into synovial cells using sonoporation

Fuminori Nagao¹, Toshiyuki Tsuzisawa², Kenjiro Iwanaga³,
Manabu Habu³, Izumi Yoshioka¹, Tatsuji Nishihara⁴, Kazuhiro Tominaga³

¹ Division of Oral Medicine, ² Department of Functional Oral Rehabilitation, School of Oral Health Science, ³ Division of Oral and Maxillofacial Surgery, ⁴ Division of Infections and Molecular Biology, Kyushu Dental University

Objective: We had confirmed the increased of interleukin-1beta (IL-1 beta) level and the decreased interleukin-1 receptor antagonist (IL-1ra) level in the synovial fluid from the patients with temporomandibular joint arthritis. Acceleration of suppressive mechanism of inflammation would be mandatory in management of arthritic conditions. In the present study, we tried to establish the sonoporation method as a new gene therapy.

Materials and Methods: HIG-82 cells, a synovial cell line derived from a rabbit knee, were used in this experiment. pVIVO1-GFP/LacZ and pCI-neo-IL-1ra were transfected into HIG-82 cells by sonoporation. To enhance the transfection efficiency, we used SonoVue™ as a micro bubble. The transfection efficiency of pVIVO-1-GFP/LacZ was examined by X-gal staining. The appearance of IL1-ra mRNA was confirmed by RT-PCR, and the expression of IL-1ra was examined by immunocytochemical analysis. IL-1ra-transfected HIG-82 cells were stimulated with lipopolysaccharide (LPS), and the amounts of IL-1beta, IL-1ra and prostaglandin E₂ (PGE₂) were examined by ELISA.

Result: Human IL-1ra mRNA was remarkably expressed in IL-1ra-transfected cells. In immunocytochemical analysis, the expression of hIL-1ra was detected in HIG-82 cells. The treatment of LPS enhanced the production of IL-1beta in HIG-82 cells and IL-1ra-transfected HIG-82 cells. IL-1ra-transfected HIG-82 cells spontaneously release IL-1ra in culture supernatant, and its level increased when the cells were cultured with LPS for 48 h. Interestingly, when IL-1ra-transfected HIG-82 cells were cultured with LPS for 60 h, a significant decrease of PGE₂ release was observed.

Conclusion: We showed that in vitro sonoporation-mediated transfer of IL-1ra plasmid had a remarkable effect on the regulation of inflammatory mediators. These findings suggest the possible application of sonoporation gene therapy using IL-1ra for the treatment of the inflammation in arthritis.

P-3 **Diet-induced obesity induces alveolar bone loss in growing mice**

Yuko Fujita, Kenshi Maki

Division of Developmental Stomatognathic Function Science,
Department of Health Promotion, Kyushu Dental University

We evaluated the age-related influence of high-fat-diet-induced obesity on bone quantity and quality in the mandible of growing mice. Male C57BL/6J mice (6 weeks old) were divided into two groups: one received a control diet and the other, a high-fat diet. After treatment for 4, 8, or 12 weeks, bone quantity and quality were assessed using micro-computed tomography and histopathology. We found significant increases in body weight and in serum total cholesterol and leptin levels in mice fed the high-fat diet, compared with the age-matched control mice. The deterioration of trabecular bone architecture and retarded growth in the periosteal surface began early in the development of diet-induced obesity and was followed by an increase in cortical bone porosity. Periodontal ligament fibers appeared disrupted, with loss of orientation from the bone surface and constriction of the periodontal ligament space was inhibited in the high-fat-diet-fed mice. Deterioration of the architecture of the trabecular bone and cortical bone is differentially regulated in mice. We demonstrated that high-fat-diet-induced obesity during growth triggered not only mandibular osteoporosis but also an increased risk of periodontal disease in later life.

P-4

Clinical application of dental magnetic attachment using the direct bonding system

Shin-ichi Masumi, Eri Makihara, Toshihiro Kawano, Mayumi Yagi,
Masahiro Arita, Keiko Nakamura, Takahiro Kawakami

Division of Occlusion & Maxillofacial Reconstruction,
Department of Oral Function, Kyushu Dental University

Dental magnetic attachment (DMA) is very useful and it has many advantages compared with other attachments such as good retention, minimal force to horizontal direction, simple structure, no reduction of retentive force, easy technical laboratory work. Although an attachment with complicated structures is difficult to wear dentures, DMA is easy to wear and remove them by the magnetic attractive force. Furthermore DMA is also easy to control of dental plaque for its simple structure. Although to create MR image degradations is the only disadvantage, it is able to cope with use the direct bonding system (DBS) of the keeper. The purpose of this report is to introduce the several kinds of clinical application of DMA applying the DBS.

The Japanese Society of Magnetic Applications in Dentistry (JSMAD) submitted the new work item proposal to receive the International Standard (ISO) of our dental magnetic attachments to the ISO/TC106 in 2007, and we received the ISO13017 in 2012. Physio magnet (Neomax, Tokyo, Japan) or Gigauss C and D (GC, Tokyo, Japan) were used to the patients. Fabrication method of a root cap for fixing a keeper is very easy by using a ready-made keeper housing pattern. After casting, a keeper is fixed by using the adhesive resin cement.

We got some advantages by using this system. Attractive force does not decrease because the keeper is set after casting of the root cap. When the needs of MR projection, the problem of the degradation is clear by removing the keeper only. Before the development of this system, we have removed the root cap before the MR projection and re-fabricated the root cap after the projection.

The DBS is very useful for the dentists who will apply DMA for the patients.

Lipopolysaccharide aggravates bisphosphonate-induced osteonecrosis in rats

Osamu Sakaguchi¹, Shinya Kokuryo², Hiroki Tsurushima²,
Jumpei Tanaka¹, Manabu Habu¹, Masataka Uehara¹,
Tatsuji Nishihara³, Kazuhiro Tominaga¹

¹Division of Maxillofacial Surgery, ²Division of Oral Medicine,
³Division of Infections and Molecular Biology, Kyushu Dental University

The pathogenesis of bisphosphonate-related osteonecrosis (BRON) of the jaw is highly controversial. Our previous study revealed that osteonecrosis was developed and promoted by periodontal pathogenic stimulation (freeze-dried *Aggregatibacter actinomycetemcomitans*; *Aa*) in both the jaw and femur in rats treated with bisphosphonate. Since one of the major toxicity factors of Gram-negative bacteria is lipopolysaccharide (LPS), the present study aimed to evaluate the relevancy between osteonecrosis and LPS in a rat model of BRON-like lesions. Male rats were subcutaneously injected with zoledronic acid (ZA) weekly for 4 weeks until performing experimental surgical procedures, then, were divided into 3 groups; the LPS group, administered LPS from *Aa* into bone marrow of the bilateral mandibles and femurs, and the LPS plus polymyxin B (PMB) and Saline groups, given neutralized LPS with PMB or saline, respectively, using the same protocol (n=5 in each group). All specimens were harvested 4 weeks after the procedure. Histological findings (hematoxylin-eosin stain) revealed significantly wider areas of osteonecrosis in both the mandible and femur of the LPS group as compared to the other groups. In the LPS plus PMB group, localized osteonecrosis was comparable to that in the Saline group. The other 2 rats which were divided into the LPS group and LPS plus PMB group were used for observations of alkaline phosphatase (ALP) and tartrate-resistant acid phosphatase (TRAP) activities by double staining with ALP and TRAP. There were fewer ALP-positive cells in the LPS than the LPS plus PMB group. There were no TRAP-positive cells around the drill hole in any of the specimens from the LPS and LPS plus PMB groups. This result suggests the possibility that ZA may have an effect to suppress osteoblast differentiation when administered in combination with LPS. Our results indicate that LPS stimulation is deeply involved in the development and promotion of BRON.

P-6 Pyroptosis and NLRP3 inflammasome activation in periodontopathic bacteria infected-macrophages are mediated by reactive oxygen species and cathepsin B

Toshinori Okinaga, Wataru Ariyoshi, Tatsuji Nishihara

Division of Infections and Molecular Biology,
Department of Health Promotion, Kyushu Dental University

Pyroptosis, caspase-1 dependent cell death, has been identified as a new pathway of host cell death, and is induced by a wide range of microbes together with inflammasome activation. In the present study, the periodontopathic bacterial pathogen, *Aggregatibacter actinomycetemcomitans*, induced pyroptosis and inflammatory responses in RAW 264.7 cells. Inflammasome component, NLRP3, ASC, and caspase-1, were upregulated during the infection of *A. actinomycetemcomitans*. The production of IL-1 β in *A. actinomycetemcomitans*-infected RAW 264.7 cells was detected by real-time reverse-transcriptase-PCR, western blotting, and enzyme-linked immunosorbent assay. Administration of a caspase-1 inhibitor downregulated IL-1 β secretion induced by *A. actinomycetemcomitans* infection. NLRP3 knockdown prevented the secretion of IL-1 β in *A. actinomycetemcomitans*-infected RAW 264.7 cells. In addition, *A. actinomycetemcomitans* infection induced the generation of reactive oxygen species (ROS) and the release of cathepsin B in RAW 264.7 cells. Interestingly, CA074-Me, a cathepsin B inhibitor, and N-Acetyl-L-cysteine (NAC), a ROS inhibitor, prevented the production of IL-1 β induced by *A. actinomycetemcomitans*. Taken together, these results suggest *A. actinomycetemcomitans* induce pyroptosis and IL-1 β production in RAW 264.7 cells by activation of the inflammasome through the production of ROS and cathepsin B.

P-7

The anti-inflammatory effect of a newly identified adipokine apelin on macrophage

Shigeyuki Obara^{1,3}, Sumio Akifusa², Michihiko Usui¹, Wataru Ariyoshi³,
Toshinori Okinaga³, Tatsuji Nishihara³, Keisuke Nakashima¹

¹Division of Periodontology, Science of Oral Functions,

²Department of Oral Health Management, ³Division of Infections and
Molecular Biology, Department of Health promotion,
Kyushu Dental University

Apelin, recently identified as endogenous ligand of orphan G protein-coupled receptor APJ, has multiple pathophysiological properties. In this study, we investigated whether pyroglutamated apelin-13 ([Pyr-1]-apelin-13), highest active isoform among the matured apelin peptide family, has property to modulate the effect of bacterial lipopolysaccharide (LPS) on cytokine induction in a murine macrophage-like cell line J774.1 cells. J774.1 cell expressed the APJ protein in stationary state, and the expression of APJ does not change with LPS stimulation. It was observed no significant effect of [Pyr-1]-apelin-13 treatment alone on the proliferation or the cytokine production in stationary state of J774.1 cells. However, prior to LPS stimulation, pretreatment with [Pyr-1]-apelin-13 for 16 hours significantly reduced the induction of inflammatory cytokines interleukin (IL)-1 β and IL-6 mRNA expression and IL-6 protein secretion, confirmed by RT-PCR and ELISA, respectively. The western blot analysis revealed that the phosphorylation of p38 mitogen-activated protein kinase (p38 MAPK) and c-Jun N-terminal kinase (JNK), but not extracellular signal regulated kinase (Erk), which were induced by LPS intoxication, clearly reduced in [Pyr-1]-apelin-13-pretreated J774.1 cells compared with the untreated cells. These observations suggest that [Pyr-1]-apelin-13 may function as a negative regulation of LPS mediated proinflammatory responses in macrophage.

P-8

Gingival epithelial cells regulate osteoclastogenesis by producing RANKL through PKA signaling.

Michihiko Usui, Keisuke Nakashima

Division of Periodontology, Kyushu Dental University

Periodontitis is a chronic inflammatory disease characterized by the destruction of alveolar bone. Receptor activator of nuclear factor kappa B ligand (RANKL) is known to be an essential factor for osteoclastogenesis. Recent clinical studies indicate that levels of RANKL in the gingival crevicular fluid are increased in periodontitis patients. Although gingival sulcus is composed of gingival tissue, RANKL expression in gingival epithelial cells (GECs) has not been fully understood.

To investigate the expression of RANKL in GECs, we examined Ca9-22 cells (human cell line), Ho-1-u-1 cells (mouse cell line) and human primary GECs. RT-PCR and western blotting analysis showed RANKL mRNA and protein were expressed by these GECs. To examine RANKL expression *in vivo*, we did immunostaining of gingival epithelium of mouse. RANKL protein expression can be seen in periodontal ligament cells and osteoblasts as reported previously. Intriguingly, RANKL positive cells exist in junctional epithelium, sulcular epithelium and oral gingival epithelium of gingival. To examine the effect of TNF- α on RANKL expression in GECs, we treated GECs with TNF- α . TNF- α increases the levels of RANKL mRNA and protein expression. To investigate mechanism TNF- α induces RANKL expression, we examined the effect of PKI (PKA inhibitor) of TNF- α -induced RANKL expression in GECs. PKI inhibited RANKL expression activated by TNF- α approximately 60%. These data indicated that TNF- α induced RANKL expression is mediated via PKA signaling. Finally, we performed *in vitro* osteoclast (OC) formation assays using bone marrow-derived murine OC precursors to determine if GECs can directly promote differentiation of OC precursors to mature OCs. Although GECs without TNF- α in co-culture system also can form any OCs, TNF- α and forskolin treatment strongly induce OC formation. These observations suggest that TNF- α induces RANKL expression through PKA signaling in GECs, which may play a role of osteoclastogenesis in progression of alveolar bone destruction by periodontitis.

Effects of MTI- II on Inflammatory Responses of Odontoblast-like Cells

Kouhei Nakayama¹, Shizu Hirata-Tsuchiya¹, Ejjiro Jimi²,
Kazuki Okamoto³, Chiaki Kitamura¹

¹ Division of Endodontics and Restorative Dentistry, ²Division of Molecular Signaling and Biochemistry, Kyushu Dental University,
³Clinical Proteomics and Molecular Medicine, St. Marianna University,
Graduate School of Medicine

Dental pulp shows inflammatory response such as the production of cytokines by a variety of cells against exogenous stimuli. One of cytokines, tumor necrosis factor α (TNF- α) is known to play important roles in the inflammatory response via NF- κ B signaling pathway. Recently, steroid-coactivator, Macromolecular Translocation Inhibitor II (MTI-II), was found to play an anti-inflammatory role in NF- κ B signaling pathway. In the present study, we examined roles of MTI-II in odontoblast-like cells (KN-3 cells) exposed to TNF- α . TNF- α did not show any effects on the proliferation of KN-3 cells with or without the transfection of MTI-II. When the cells were treated with TNF- α , NF- κ B-luciferase activity was induced, whereas alkaline phosphatase (ALP) activity was inhibited, in a TNF- α dose-dependent manner. In contrast, overexpression of MTI-II in the cells failed to increase TNF- α -induced NF- κ B-luciferase activity. Furthermore, overexpression of MTI-II restored TNF- α -mediated inhibition of osteocalcin and ALP expression in KN-3 cells. These results suggest that MTI- II may suppress inflammatory responses of KN-3 cells through a down-regulation of transcriptional activity of NF- κ B by TNF- α , and that the application of MTI-II may be useful for the regulation of inflammatory responses of dental pulp.

P-10 Changes of muscle pain and mandibular movements by splint therapy in patients with masticatory muscle disorders –a short term study-

Ryuichirou Miyajima, Toshihiro Kawano, Shin-ichi Masumi

Division of Occlusion & Maxillofacial Reconstruction,
Department of Oral Function, Kyushu Dental University

The purpose of this study was to examine whether muscle pains, mandibular movements and the occlusal condition of TMD patients with masticatory muscle pains change by the splint therapy.

Five subjects who had masticatory muscle pains were enrolled in this study. All subjects gave informed consent before taking part in this experiment. A stabilization splint was made for each subject on upper jaw. Measurement items were the distances of protrusive and lateral border movements, the occlusal condition, VAS of subjective symptoms and pressure pain thresholds in masseter and temporalis muscles before and after the splint wearing. The measurements of protrusive and lateral border movements were performed with a Gothic display (SHOFU) and the occlusal condition was analyzed using the Occluser (GC). The data acquisition was carried out before and 2 weeks after wearing of the stabilization splint. Paired-t test was carried out to evaluate the significance of differences.

The distances of protrusive and lateral border movements significantly increased after the splint wearing. Bite force (N), occlusal contact points, occlusal contact area (mm²), showed a decreasing tendency after the splint wearing, but there were no statistically significant differences. VAS values showed the decline after the splint wearing, and pressure pain thresholds increasing tendency after the splint wearing.

It has been found that muscle pains were relieved, and the distances of mandibular movements increased for patients with a masticatory muscle disorders by the splint therapy. In addition, the occlusal condition in patients with masticatory muscle disorders might change.

P-11 The relationship between morphological characteristics of face and occlusal force in dental students

Taiji Nakamura, Masaki Morishita, Kosuke Muraoka, Michihiko Usui,
Keisuke Nakshima

Division of Periodontology, Department of Oral Function,
Kyushu Dental University

Occlusal force is one of the risk factors for progression of periodontal disease, as the excessive force accelerates periodontal destruction. Although it is generally speaking that a person with a squarish face has greater occlusal force compared with an oval face, researches for relationship between morphological characteristics of face and occlusal force are very few. The aim of present study was to determine correlations between facial morphological characteristics and occlusal force using a full-faced photograph and a measuring device for bite force. A total of fifty dental students in Kyushu Dental University were participated (32 men and 28 women, 23.3 ± 2.9 years of age). Facial shot was taken with a digital camera and occlusal force was measured with Occuluser FDP707 (GC Corp. JAPAN) for each subject. Photo images were then incorporated in a computer, and evaluated with Image J software (NIH, USA). Length and width of face, the width of the lower jaw, the area of face, the thickness of lips, the gonial angle, and the angle of convexity were measured on the incorporated image. The occlusal force showed a significant positive correlation with the width of the lower jaw ($R^2=0.12$) and the gonial angle ($R^2=0.16$). These results suggest that some morphological characteristics of face are related with occlusal force.

P-12 **Immunohistochemical analysis of a putative osteocalcin receptor involved in glucose homeostasis**

Sen Higashi¹, Akiko Mizokami², Tomoko Ohsumi¹, Masato Hirata²,
Hiroshi Takeuchi¹

¹Division of Applied Pharmacology, Kyushu Dental University,
²Laboratory of Molecular and Cellular Biochemistry,
Faculty of Dental Science, Kyushu University

Bone-derived protein osteocalcin (OC) stimulates insulin secretion, thus regulating energy metabolism in target tissues. A G-protein coupled receptor, GPRC6A, has been identified as a putative receptor for OC which mediates insulin secretion in pancreas. We have found that OC also stimulates insulin secretion through stimulating glucagon-like peptide-1 (GLP-1) secretion from the gut. However, the localization of GPRC6A, particularly regarding the relationship with the cells secreting hormones remains elusive.

In the present study, we examined the distribution of cells expressing GPRC6A in mouse tissues and compared with those of several molecules related to systemic glucose homeostasis by immunohistochemistry. In small intestine, a portion of GPRC6A positive cells were co-localized with GLP-1, supporting our previous report on OC effect. In pancreas, β -cells showed relatively high expression of GPRC6A throughout Langerhans islets, while the unidentified peripheral cells surrounding β -cells in the islets were also positive to GPRC6A signals. The results suggest that GPRC6A contributes to regulation of several hormones including insulin and incretins.

P-13

Diagnostic accuracy of oral exfoliative cytology in Kyusyu Dental University

Naomi Yada, Kou Matsuo

Division of Oral Pathology, Department of Health Promotion,
Kyushu Dental University

Exfoliative cytology of the oral cavity is a quick, simple, and economical procedure based on a relatively atraumatic semi-invasive technique. However, cytology is not preferred in cases of oral lesions because biopsy is easier to perform. The present study was designed to determine the diagnostic accuracy of oral exfoliative cytology in Kyusyu Dental University. The samples comprised cytological and histological specimens from 136 cases. These 136 cases were cytologically divided into four groups: 72 negative cases, 58 suspicious cases, 6 positive cases, and 0 insufficient cases. Eleven cases (8.0%) were false-negative and 15 (11.0%) were false-positive. Statistical analysis of the 136 oral exfoliative cytological cases with a histological diagnosis showed a sensitivity of 81.7%, specificity of 80.2%, and accuracy of 80.9%. Clinical examination revealed that nine of 11 false-negative cases had leukoplakia. A thick hyperkeratotic layer hindered sampling of lesions, thereby resulting in failure of diagnosis by prohibiting access to the deeper cells of epithelial dysplasia. Eight of 15 false-positive cases had reactive atypia to inflammation of the gingiva. In conclusion, exfoliative cytology of oral lesions is adequate for screening, however, more cytological and clinical findings should be accumulated for improving diagnostic accuracy.

P-14 **Magnetic resonance angiography with fresh blood
imaging for identification of hemangiomas and around blood
vessels in oral cavity**

Masafumi Oda, Tatsuro Tanaka, Shinji Kito, Nao Wakasugi-Sato,
Shinobu Matsumoto-Takeda, Shun Nishimura, Yasuhiro Morimoto

Division of Oral and Maxillofacial Radiology, Kyushu Dental University

The purpose of this study is to evaluate fresh blood imaging (FBI), a magnetic resonance imaging technique that does not use contrast, for identifying hemangiomas and feeding arteries in the oral cavity. For 16 patients with hemangiomas, FBI visualizations of hemangiomas and feeding arteries in the oral cavity were compared with those from 3-dimensional (3D) phase-contrast magnetic resonance angiography (PC-MRA). We compared the two MR sequences based on the conspicuities of blood vessels and the 3D relationships of hemangiomas with the surrounding blood vessels. The conspicuity of hemangiomas, feeding arteries, and blood vessels were significantly better with FBI than with PC-MRA. After differentiating arteries from veins, 3D visualizations of hemangiomas and arteries or veins could be performed with FBI. Thus, our experience shows that FBI is a useful method in oral cavity for identifying the relationships between hemangiomas and the surrounding arteries or veins.

P-15

Expression of GAD67 and Dlx5 in taste buds of mice genetically lacking Mash1

Yuji Seta¹, Ayae Kito-Shingaki^{1,2}, Takashi Toyono¹, Shinji Kataoka³,
Yasuaki Kakinoki², Yuchio Yanagawa⁴, Kuniaki Toyoshima¹

Division of ¹Oral Histology and Neurobiology,

²Oral Care and Rehabilitation Special Needs and Geriatric Dentistry,

³Oral Anatomy, Kyushu Dental University,

⁴Department of Genetic and Behavioral Neuroscience, Gunma University
Graduate School of Medicine

It is reported that subset of type III taste cells expressed glutamate decarboxylase (GAD) 67, a molecule synthesizing gamma-aminobutyric acid (GABA), and that Mash1 could be potential regulator of the development of GABAergic neurons via Dlx transcription factors in the central nervous system. In the present study, we investigated the expression of GAD67 and Dlx in embryonic taste buds of soft palate and circumvallate papilla using Mash1 KO/GAD67-GFP knock-in mice. In wild type animal, subset of type III taste cells had GAD67 in the taste buds of the soft palate and developing circumvallate papilla, and those GAD67 expressing taste bud cells were missing Mash1 KO mice. A subset of type III cells expressed mRNA for Dlx5 in wild type animals, and those Dlx5 expressing cells were not evident in apical part of circumvallate papilla and taste buds in the soft palate of Mash1 KO mice. The present results suggest that Mash1 is required for the expression of GAD67 and Dlx5 in the taste bud cells.

P-16

Why do we feel thirsty in hangover?

Izumi Ujihara^{1,2}, Kiyotoshi Inenaga¹, Suzuro Hitomi¹, Kentaro Ono¹,
Yasuaki Kakinoki²

¹Division of Physiology, ²Division of Oral Care and Rehabilitations,
Kyushu Dental University

In hangover, people experience heavy thirst. The metabolite of EtOH acetaldehyde (ACD) has never been considered to be a thirst inducing factor in hangover. Recent studies show that ACD activates mast cells and elicits renin release. We hypothesized that ACD is a factor inducing thirst sensation in hangover. Male Wistar rats were used in the present study. EtOH significantly increased water intake. Coadministration of the ACD dehydrogenase inhibitor cyanamide with EtOH increased both water and salt intake further and earlier. ACD with cyanamide more rapidly elicited water and salt intake. Urination was less found in the early stage even in the administration of ACD and cyanamide. When allowed to drink water and salt solution, urine volume was increased only after drinking, suggesting that urination is not a main trigger for initiation of drinking behavior. The elicited water and salt intake were suppressed by intraperitoneal and intracerebroventricular injections of AT1 antagonist candesartan. The drinking behavior was also suppressed by the mast cell membrane inhibitors cromolyn and doxantrazole. Immunohistochemical study showed that EtOH (and ACD) increased the number of c-Fos immunopositive neurons in the brain regions of thirst center. Taken together, thirst sensation in hangover of alcohol may be induced through renin secretion from mast cells and AT1 receptor activation of neurons in the thirst center of the brain in rats.

P-17 The basic study of the bone resorption in type II diabetic periodontitis

Min Zhang¹, Kou Matsuo¹, Eijiro Jimi²

¹Division of Oral Pathology, ²Devision of Molecular Signaling and Biochemistry, Department of Health Promotion, Kyushu Dental University

Non-insulin-dependent type II diabetes mellitus causes serious complications such as hypertension and arteriosclerosis as well as diabetic periodontitis. Furthermore, in many cases, treatment for usual periodontitis does not work effectively enough for diabetic periodontitis, and the solution to this issue including its pathogenic mechanism is not clear yet. The purpose of this experiment in diabetic periodontitis is to clarify the peculiar development mechanism on a cellular and molecular level, and to develop a therapeutic agent to cure diabetic periodontitis. We used a type II diabetes model *db/db* mouse and wild-type mouse, and took the images of their mandible by using μ CT. The result showed remarkable decrease of the alveolar bone in model *db/db* mouse. Whereat, we have prepared a bone marrow cell from both mice's tibias and femurs, and added osteoclast lead factor, RANKL, for stimulation. As a result, the induced amount of the osteoclasts of *db/db* mouse were much greater compared with that of the wild-type mouse. With the above mentioned results, we consider that the acceleration of the osteoclast differentiation in the bone marrow environment plays a part in diabetic periodontitis.

P-18

The mechanism of oral ulcer-induced pain hypersensitivity in rats

Suzuro Hitomi, Kentaro Ono, Sachiko Kuramitsu, Kiyotoshi Inenaga

Division of Physiology, Department of Health promotion,
Kyushu Dental University

Oral ulcer induces pain during food consumption and speaking. Because of absence of animal assay to evaluate intraoral pain-induced behaviors, pain mechanism in oral ulcer is unclear. In this study, we investigated pain sensitivities to mechanical and chemical stimulations in oral ulcer using our newly developed behavioral assays in conscious rats: (1) measurement of head withdrawal threshold to mechanical stimulation to oral mucosa in trained rats with piercing of the mouth and (2) observation of nocifensive grooming-like behaviors following dropping of chemical solution. Treatment with acetic acid in the labial fornix region of the inferior incisors developed obvious oral ulcer, showing severe infiltration of inflammatory cells and epidermolysis in histology. Head withdrawal threshold to mechanical stimulation to the oral mucosa was significantly decreased in oral ulcer compared to sham. Furthermore, topical treatment with xylocaine in the region of the oral ulcer significantly increased the mechanical pain threshold, but the anesthetic effect was considerably less than that in the healthy oral mucosa. Grooming-like behaviors following dropping of capsaicin and citric acid solutions (hot and sour tastes, respectively) were significantly enhanced by oral ulcer development. In immunofluorescence, there were no differences in expression levels of transient receptor potential vanilloid 1 (TRPV1) and amiloride-sensitive acid-sensing ion channel 3 (ASIC3) in trigeminal ganglion between sham and oral ulcer model rats. These results suggest that oral ulcer induces pain hypersensitivity to chemical and mechanical stimulations, probably due to tissue damage and inflammation without changes of TRPV1 and ASIC3 expressions.

P-19

A prospective study of changes in Oral Health-Related Quality of Life measurements during immediate function implant procedures for edentulous individuals

Saori Misumi, Tetsuji Nakamoto, Yusuke Kondo, Taro Mukaibo,
Chihiro Masaki, Ryuji Hosokawa,

Department of Oral Reconstruction and Rehabilitation,
Kyushu Dental University

Objective: The aim of this longitudinal clinical study was to evaluate changes in oral health-related quality of life (OHRQoL) measurements during immediate-function implant treatment for edentulous individuals.

Materials and Methods: Ten edentulous patients had 4 to 6 implants placed in each jaw, and provisional restorations were applied immediately. The acrylic provisional restoration was refabricated 3–6 months after the implant placement surgery, and then final restorations with metal framework were introduced. OHRQoL measurements were obtained using the Japanese shortened version of oral health impact profile before the implant placement surgery, 1 week after the immediate restoration, 1 week after the secondary acrylic provisional restoration, and at a maintenance visit. Complete data were collected for 9 subjects and were statistically analyzed.

Results: The OHRQoL significantly improved upon the secondary restoration and final restoration, but not at immediate restoration, when each score was compared with the baseline status ($p < 0.05$). Of all categories, significant improvements in “functional limitation” and “physical disability” were observed when the final metal framework restorations were placed. “Psychological discomfort” and “psychological disability” showed significant improvement upon secondary restoration. “Social disability” and “handicap” remained unchanged during the observation period.

Conclusion: When immediate-function implants are used for edentulous individuals, patient satisfaction is obtained to a limited degree by acrylic restoration. However, final restoration with metal framework is more effective in improving patients’ OHRQoL.

P-20 Pulp revascularization of an immature permanent tooth
with apical periodontitis using mineral trioxide
aggregate (MTA) : a case report

Katsura Saeki, Yasuhiro Shiono, Ayako Sugiyama, Kenshi Maki

Division of Developmental Stomatognathic Function Science,
Department of Health Promotion, Kyushu Dental University

Mineral trioxide aggregate (MTA) is a material that has been used worldwide in several clinical applications, such as apical barriers in teeth with immature apices, repair of root perforations, root-end filling, pulp capping, and pulpotomy.

We describe successful revascularization treatment of an immature mandibular right second premolar with apical periodontitis in a 9-year old patient. Using no anaesthetic, the tooth was isolated using a rubber dam and accessed. The canal was gently debrided using 5% sodium hypochlorite (NaOCl) and 3% hydrogen peroxide irrigant. And then MTA was packed into the canal. X-ray photographic examination showed the dentin bridge 5 months after the revascularization procedure. Thickening of the canal wall and complete apical closure was confirmed 10 months after the treatment.

In this case, MTA showed clinical and radiographic success at revascularization treatment in immature permanent tooth.

The successful outcome of this case suggests that MTA is reliable and effective for endodontic treatment in the pediatric dentistry.

P-21

Functional modulation of adipocyte by osteocalcin

Shintaro Tsuka^{1,2}, Ryuji Hosokawa¹, Hiroshi Takeuchi²

¹Department of Oral Reconstruction and Rehabilitation,

²Division of Applied Pharmacology, Kyushu Dental University

A close relationship between bone and systemic glucose metabolism has been studied extensively and uncarboxylated form of osteocalcin (ucOC) was recently shown to play a key role in energy metabolism. However, the molecular mechanism of the ucOC action is still largely unknown. In the present study, we examined the effect of ucOC on 3T3-L1 adipocytes to clarify how ucOC regulates energy metabolism. 3T3-L1 pre-adipocytes were grown to confluence in Dulbecco's modified Eagle medium (DMEM), followed by differentiation to adipocytes by adding 0.5 mM isobuthylmethylxanthine, 0.25 μ M dexamethasone and 100 nM insulin for 48 hr. The medium was replaced with adipocyte growth medium (AGM:DMEM with 4500 mg/l glucose, 10% fetal bovine serum, antibiotics) containing 100 nM insulin for 48 hr, and then replaced with AGM alone every 2 days. The differentiated adipocytes were exposed to various concentrations of ucOC and then, the conditioned medium and the cell lysate were subjected to analysis by enzyme-linked immunosorbent assay and western blotting. ucOC promoted both expression and secretion of adiponectin with the maximum effect at the concentration between 5 and 10 ng/ml. ucOC also induced phosphorylation of Erk and increased expression of PPAR γ . Inhibition of Erk phosphorylation by a MEK inhibitor (U0126), but not a PI3K inhibitor (LY294002) suppressed both ucOC-induced expression of PPAR γ and increased secretion of adiponectin. These results suggested that ucOC promotes expression and secretion of adiponectin through Erk-PPAR γ -dependent signaling pathway.

P-22

New selective inhibitor of NF- κ B inhibits bone invasion
by oral squamous cell carcinoma

Yukiyo Tada^{1,2}, Goro Sugiyama², Seiji Watanabe¹, Eijiro Jimi²

¹Division of Dental Anesthesiology,

²Division of Molecular Signaling and Biochemistry,
Kyushu Dental University

Oral squamous cell carcinoma (OSCC) is the most common malignant tumor of the oral cavity, head and neck. The bone invasion by OSCC is a critical factor for metastasis, and affects the prognosis of patients. Nuclear factor- κ B (NF- κ B) is constitutively activated in many cancers including OSCC, and is involved in the invasive characteristics of OSCC. We previously reported that a selective inhibitor of NF- κ B inhibited bone invasion by OSCC in mouse model. In this study, we examined the effects of novel NF- κ B inhibitor, IMD-0560, which is known to use for the clinical trial for rheumatoid arthritis (RA), on bone invasion by OSCC in vitro and in vivo. IMD-0560 inhibited basal and TNF α -induced NF- κ B activation in human OSCC, Ca9-22, HSC-2, and mouse SCCVII. Moreover, IMD-0560 prevented TNF α -induced migration and matrix metalloproteinase 9 (MMP9) activity of OSCC. We also investigated the effect of IMD-0560 on bone invasion by OSCC using bone invasion mouse model. Mice injected with OSCC to the left mandibular region showed clearly tumor growth and zygomatic bone destruction. Treatment with IMD-0560 (3 or 5 mg/kg) suppressed both tumor growth and zygomatic bone destruction in a dose dependent manner, suggesting that IMD-0560 inhibited bone invasion by OSCC via suppressing NF- κ B activation. IMD-0560 might be useful for preventing bone invasion by OSCC.

P-23 RelB-induced Cot expression rescues RANKL-induced osteoclastogenesis by Cot/IKK α -induced NF- κ B2 processing

Rei Taniguchi^{1,2}, Hidefumi Fukushima³, Kenshi Maki², Eijiro Jimi¹

¹Division of Molecular Signaling and Biochemistry, ²Division of Developmental Stomatognathic Function Science, Department of Health Improvement, Kyushu Dental University, ³Department of Physiological Science and Molecular Biology, Fukuoka Dental College

The transcription factor NF- κ B regulates the expression of a wide variety of genes that are involved in immune and inflammatory responses, proliferation, tumorigenesis, and survival. NF- κ B activation pathway consists of two distinct pathways, termed the classical and alternative NF- κ B signaling pathways. We have previously reported that alymphoplasia (*aly/aly*) mice, which have a natural loss-of-function mutation in the *Nik* gene that encodes a kinase that is essential for the processing of p100 to p52 in the alternative NF- κ B pathway, show mild osteopetrosis due to inhibition of osteoclastogenesis. p100 retains RelB in the cytoplasm and inhibits RANKL-induced osteoclastogenesis in *aly/aly* cells. In this study, we show here that the overexpression of RelB, but not p65, in *aly/aly* cells rescues RANKL-induced osteoclastogenesis by inducing p100 processing. However, the overexpression of RelB fails to rescue RANKL-induced osteoclastogenesis in the presence of a mutant form of p100, p100 Δ GRR, which cannot be processed to p52, suggesting that p100 processing is a key step in RelB-restored, RANKL-induced osteoclastogenesis in *aly/aly* cells. Finally, we found that Cot (Cancer Osaka thyroid) was upregulated by RelB overexpression, and knocking down Cot expression significantly reduced the RANKL-induced osteoclastogenesis induced by RelB overexpression. Furthermore, the phosphorylation of IKK α at threonine 23 and its kinase activity were indispensable for the processing of p100 and osteoclastogenesis by RelB-induced Cot. Taken together, these results indicate that the overexpression of RelB restores RANKL-induced osteoclastogenesis by activation of Cot/IKK α -induced p100 processing.

講堂2階

